

October 2011

# Spine Clinics

Spinal Metastasis - Diagnosis and Treatment

Permit No.MICA (P) 078/10/2011

Division of Spine Surgery -  
Orthopaedic International



**Dr Tan Chong Tien**

MBBS(Melbourne) FRCS (Edinburgh)  
FAMS (Orthopaedics)  
Past Director of Spine Service, SGH  
Past President Singapore Orthopaedics  
Association  
Membership: Scoliosis Research Society  
Asian Academy of Minimally Invasive Spinal  
Surgery



**Dr Ngian Kite Seng**

MBBS (Singapore) FRCS (Edin)  
FRCS (Glasgow) FAMS (Ortho)  
International Affiliate Member American  
Association of Orthopaedic Surgeons  
Member, Asian Academy of Minimally Inva-  
sive Spinal Surgery (AAMISS)  
Member, AOSpine International



**Dr Tan Siah Heng James**

MBBS (Singapore) FRCS (Edinburgh)  
FRCS (Glasgow),  
FRCS (Neurosurgery)  
Past Director of Spine Programme NNI ,  
Comm Member, East Asia, AO Spine Intl  
Member AO Spine International  
Member, Clinical Neuroscience Society

## Welcome

Welcome to our November issue of Spine Clinics. We will be putting up our past articles onto the web soon. Do be on the lookout for the link. In this issue, we are sharing our experience with the commonest spinal tumour - metastatic spinal secondaries. Management of this common condition is dictated by many factors. The main concern is always the stability of the spine and the protection of the delicate spinal cord.

### Case Study

Madam B, a 72 year old female, presented to my clinic recently with 3 months history of low back pain radiating to her left supra-iliac region. Her symptom had worsened progressively. She had tenderness elicited by lumbar spine flexion. Neurological examination of her lower limbs was normal. X-ray and MRI of her spine revealed an extensive infiltrative lesion of T11 vertebral body and it's left pedicle. The posterior wall of the vertebra was eroded and the lesion was encroaching onto the spinal cord and compressing it. The assessment was an extensive T11 spinal metastasis with cord compression and high risk of pathological fracture that could result in paralysis. Madam B underwent T11 decompression laminectomy with clearance of tumour tissue immediately surrounding the cord. The spine was instrumented from T8 to L1 segments to provide stability and to pre-empt pathological fracture. Frozen section of the specimen taken during surgery indicated the lesion to be lymphoma. This was later sub-typed as diffuse large B-cell lymphoma. Her back pain resolved completely following the surgery and she was ambulating well. She was referred to haematologist for outpatient chemotherapy treatment which started one week following the surgery.

### Diagnosis

There are potential pitfalls in the diagnosis of spinal metastasis. Spinal metastasis may not be suspected because it is a less common cause of back pain. Metastatic lesions may not be obvious on X-Ray until extensive bone destruction has taken place. Hence a strong index of suspicion is needed to pick up the diagnosis early. When diagnosis is suspected, MRI is the most useful investigation to demonstrate the extent of the lesion and the state of cord compression. Bone scan is useful to search for other sites of bone involvement. PET scan is useful to demonstrate sites of other organ metastasis. Histological diagnosis of specimen obtained through percutaneous biopsy or open surgery is ultimately needed for guiding treatment.

### Treatments

Treatments of spinal metastasis may include chemotherapy, radiotherapy, immunotherapy, and surgery. A combination of these methods is often needed. In considering treatments of spinal metastasis, one has to take into account many factors.

#### a. Histogenesis.

This will determine the responsiveness of the tumour to chemotherapy, radiotherapy, hormonal or immunotherapy.

**b. Extent of the metastatic lesion.**

This may cause spinal instability and cord compression if there is extensive tumour growth.

**c. Other sites of spinal involvement or other organ metastasis.**

This indicates the extent of the disease.

**d. The general health of the patient and the life expectancy.**

Patient's condition may be so poor that surgical intervention becomes too risky.

**e. Potential complications of the treatments recommended.**

Side effects of the recommended treatments have to be weighted against their benefits.

**Roles of surgery**

**a. Percutaneous biopsy.**

A CT guided needle biopsy for an accessible lesion has the advantage of being a minimally invasive procedure. However the yield may not be adequate to provide for a detailed histological analysis.

**b. Open biopsy.**

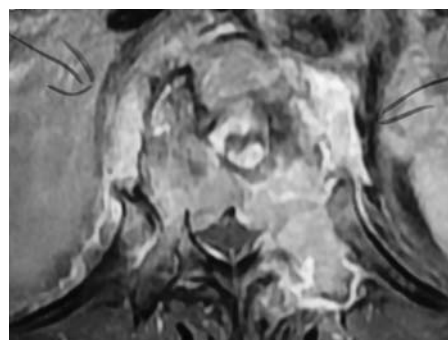In case of failed needle biopsy or when liberal amount of tissue specimen is critical, open biopsy should be employed.

**c. Percutaneous biopsy and vertebroplasty/kyphoplasty.**

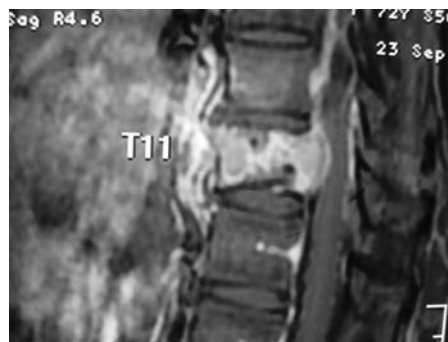
Following biopsy, bone cement is injected into the vertebral body. This often gives good relief of pain. The procedure should be contemplated only if the wall of the vertebral body, especially posterior wall, remains intact. Otherwise there is the risk of bone cement leakage into the spinal canal.

**d. Surgical decompression, instrumentation and fusion.**

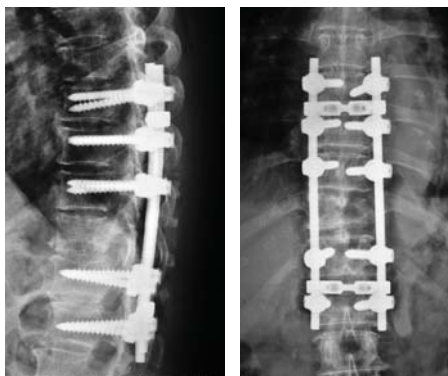
Surgical approaches may be anterior or posterior. Sometimes a combination of both approaches is necessary. Surgery is needed if patient presents with deteriorating neurological deficit due to spinal cord compression, or when there is imminent risk of pathological vertebral fracture. Radiotherapy or chemotherapy may not be able to remove fast enough the tumour compressing the cord. They also can not address the pain arising from spinal instability due to pathological fracture. Speedy surgical decompression is needed in such circumstance to preserve the spinal cord function. Following surgery, patient will have good pain relief and can be treated with chemotherapy or radiotherapy without fear of losing the neurological function.



Extensive metastasis at T11 with cord compression T11 metastasis



T11 metastasis



T11 decompression laminectomy and T8 to L1 instrumentation

**Summary**

Spinal metastasis is frequently diagnosed late and requires a high index of suspicion in order to reach early diagnosis. Histological diagnosis is critical for guiding the mode of treatment. Most of the spinal metastasis are treated with a combination of chemotherapy, radiotherapy, immunotherapy or hormonal therapy. Vertebroplasty /kyphoplasty are useful for painful metastasis with intact posterior vertebral wall. Open decompression surgery with spinal instrumentation is still needed in situation of spinal cord compression and instability from pathological fracture.

By Dr C T Tan, email: ctiantan@singnet.com.sg.

*Orthopaedics International, Neurosurgery International and Sports Medicine International* are a group of registered specialist practices comprising 8 orthopaedic surgeons, a neurosurgeon and a sports physician. Operating out of 4 locations within Singapore, we aim to provide patients with comprehensive and professional care for all musculoskeletal, neurosurgical and sports-related conditions. Each specialist brings a range of interests, expertise and sub-specializations to the group, and is also a senior doctor with a minimum of 20 to 30 years of relevant clinical experience behind him. We strongly believe in a team approach, so that every patient of ours will be treated with the highest standards of expertised care that are available.

**Our Locations :**

**Camden**



#03-02 Camden Medical Centre  
1 Orchard Boulevard  
Singapore 248649  
Tel : 6836 9688  
Fax : 6836 6869

**Mt. Alvernia**



#02-33 Mt. Alvernia Medical Centre Blk B  
820 Thomson Road  
Singapore 574623  
Tel : 6352 7678  
Fax : 6352 7680

**Gleneagles**



#02-42 Gleneagles Hospital Annexe Block  
6A Napier Road  
Singapore 258500  
Tel : 6476 7266  
Fax: 6476 2066

**Mt. Elizabeth**



#05-08 Mt Elizabeth Medical Centre  
3 Mt Elizabeth  
Singapore 228510  
Tel : 6737 6386  
Fax : 6737 6836

**Registered Practices :**



Orthopaedics International  
a member of SCMR



Sports Medicine International  
a member of SCMR



Neurosurgery International  
a member of SCMR

www.ortho-intl.com  
www.sports-med-intl.com  
www.neuro-intl.com